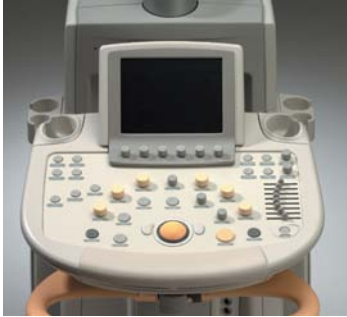

Doppler effect is, however, applicable to any kind of wave, whether electromagnetic or mechanical, and thus also to ultrasound.

The fact that the Doppler frequency shift could be used for the detection of blood velocity patterns, was shown in 1959. And the first combined use of standard (B-mode) ultrasonography and pulsed Doppler velocity detection, introducing the term duplex scanning occurred in 1974. Color Doppler sonography with its color coding of blood flow velocities, was introduced in the 1980s, followed by power Doppler sonography in the early 1990s.



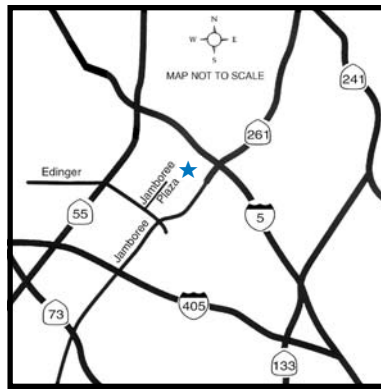
*Advanced Veterinary Medical Imaging's new Philips iU-22 ultrasound system.*

### ***Tissue harmonic imaging***

One of the most recent advancements in ultrasound technology is tissue harmonic imaging. Tissue harmonic imaging makes use of lower frequency sound waves to improve penetration, while receiving and processing only the higher frequency echoes produced by the body's inherent harmonic characteristics. This process can reduce clutter and improve image clarity significantly.

### ***Ultrasound at AVMI***

Advanced Veterinary Medical Imaging has acquired the latest in premium level ultrasound imaging. Our new Philips iU22 ultrasound system has dramatically enhanced the diagnostic imaging services we provide. Offering unprecedented image quality and sensitivity, this system can help us visualize abnormalities sooner, which can translate into earlier detection and treatment for our patients.



**Directions:**  
**From San Diego and South Orange County:**  
5 North. Exit Jamboree. Turn left on Jamboree, follow the signs to Edinger Ave. Turn right on Edinger to Jamboree Plaza Rd. Turn right into the Jamboree Plaza.

**From Inland Empire:**  
91 West to either 241 toll road, 55 or 57 freeways to 5 South. Exit Jamboree Rd., turn right on Jamboree, follow the signs to Edinger Ave. Turn right on Edinger to Jamboree Plaza Rd. Turn right into the Jamboree Plaza.



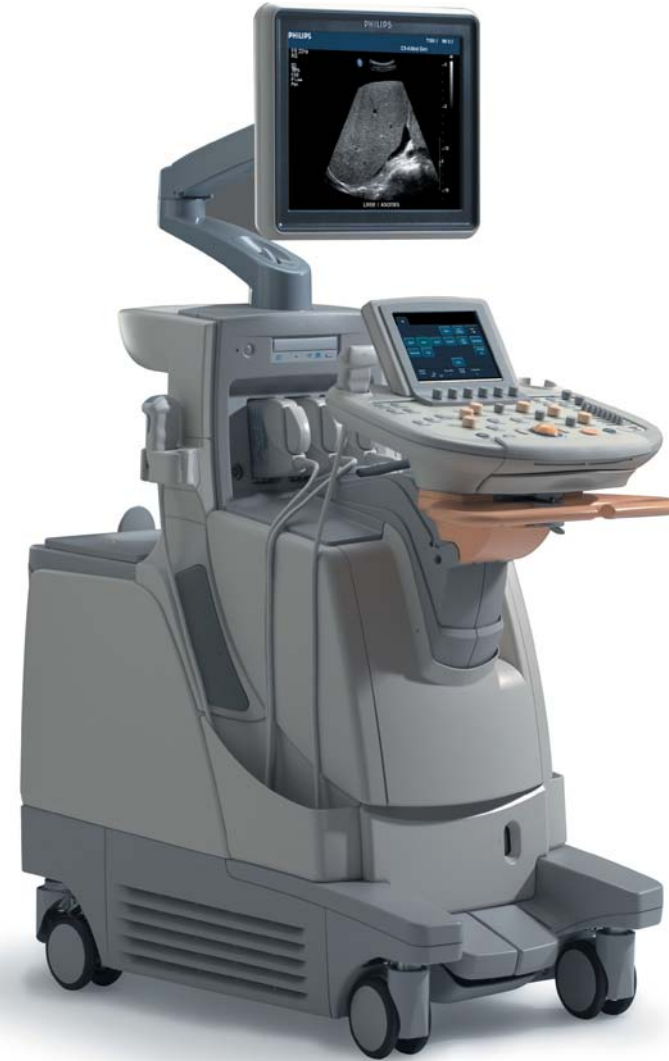**From San Bernardino area:**  
605 South to 5 South. Exit Jamboree. Turn right on Jamboree, follow the signs to Edinger Ave. Turn right on Edinger to Jamboree Plaza Rd. Turn right into the Jamboree Plaza.

**From LA/Long Beach area:**  
405 South. Exit Jamboree. Turn left on Jamboree Rd. to Edinger Ave. Turn left on Edinger to Jamboree Plaza Rd. Turn right into the Jamboree Plaza.



Our building is in the back of the Jamboree Plaza business complex immediately opposite the Metrolink Parking lot.

**Advanced Veterinary Medical Imaging**  
3047 Edinger Ave. Tustin, CA 92780  
Toll Free: 800-717-AVMI  
Tel: 949-559-7289  
Fax: 949-559-6727  
[www.avmi.net](http://www.avmi.net)



# Ultrasound

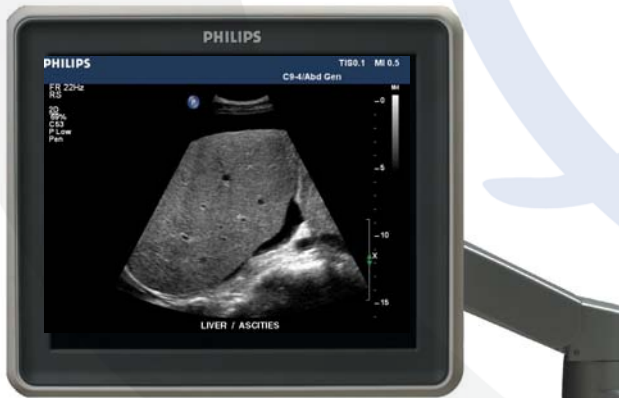**Ultrasonography** is a diagnostic imaging modality that generates images of internal organs and tissues by measuring the returning echoes from ultrasound waves generated by a hand held transducer.

### Short historical review

Man's practical use of ultrasound had to await the discovery of the piezoelectric crystal. Piezoelectric crystals are used in ultrasound transducers to transmit and receive ultrasound.

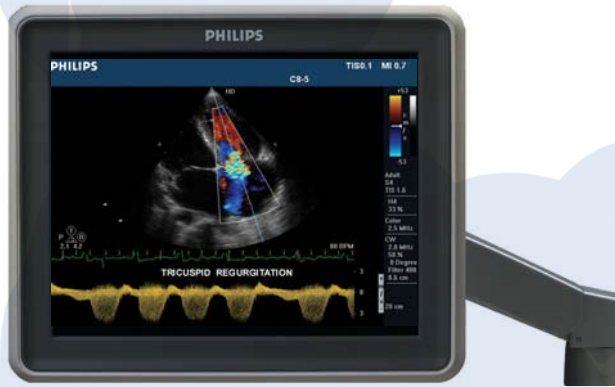**Piezoelectric effect:** The phenomenon that certain crystals change their physical dimensions when subjected to an electric field, and vice versa; when deformed by external pressure, an electric field is created across the crystal (from the Greek word piezein = pressure).

In 1880, the brothers Jacques and Pierre Curie demonstrated the piezoelectric effect which makes possible the generation and detection of high-frequency pressure waves. The ability of a piezoelectric crystal to emit ultrasound as a beam in a predetermined direction and to detect the echoes reflected from objects struck by the beam, was first exploited in World War I in the detection of



**Figure 1. Longitudinal scan of the liver revealing a mild ascites (free abdominal fluid).**

enemy submarines. This technique was later developed into the well-known SONAR (sound navigation and ranging) system. The first published attempt to use ultrasound for medical diagnosis did not appear until 1942, when K.T. Dussik tried to use transmitted ultrasound through the intact skull to diagnose brain tumors. The attempt was, however, unsuccessful. In 1949, G.D. Ludwig and F.W. Struthers authored the first publication on the use of the pulse - echo technique for medical diagnostic imaging.



**Figure 2. Cardiac scan using color flow Doppler and Pulsed wave Doppler in duplex mode to demonstrate tricuspid regurgitation.**

### Physical principle

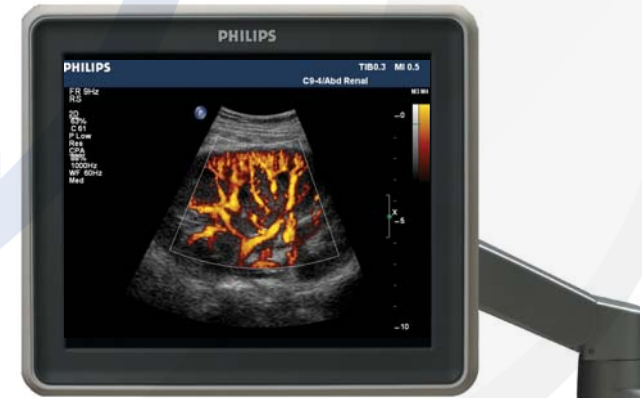All diagnostic ultrasonography is based on the pulse echo method in which an ultrasound transducer transmits brief pulses of ultrasound that propagate into the tissues. Each pulse travels in a narrow ultrasound beam, the shape of which is determined by the dimensions of the transducer, the ultrasound wavelength and the degree of mechanical or electronic focusing. The propagational speed (speed of sound) of the ultrasound pulses is determined by the elasticity and density of the medium, and is nearly constant in the soft tissues

of the body (approximately 1540 m/s). Whenever there is a change in acoustic impedance, some of the ultrasound is reflected or backscattered to the transducer as echoes. The duration of each pulse is in the order of 1-2  $\mu$ s, and the pulse repetition frequency PRF is typically 1-5 kHz (1000-5000 pulses per second). Between pulse transmissions, i.e. approximately 99.7-99.9 % of the time, the transducer serves as a detector of the echoes.

Acoustic impedance is the property of tissue causing resistance to the propagation of ultrasound.

### Doppler Effect

The Doppler effect was first described by the Austrian mathematician and physicist, Johann Christian Doppler (1803-1853). In his famous article of 1842, he describes how the phenomenon affects the observed light waves from stars having a movement relative to the observer. If the star is moving towards the observer, the frequencies of the observed light waves are slightly higher than the emitted frequencies, and vice versa. The change in frequency can be used to estimate the speed of the star relative to the observer. This



**Figure 3. Longitudinal scan of a kidney using power Doppler to demonstrate blood flow through the renal vasculature.**