ADVANCED
VETERINARY MEDICAL IMAGING

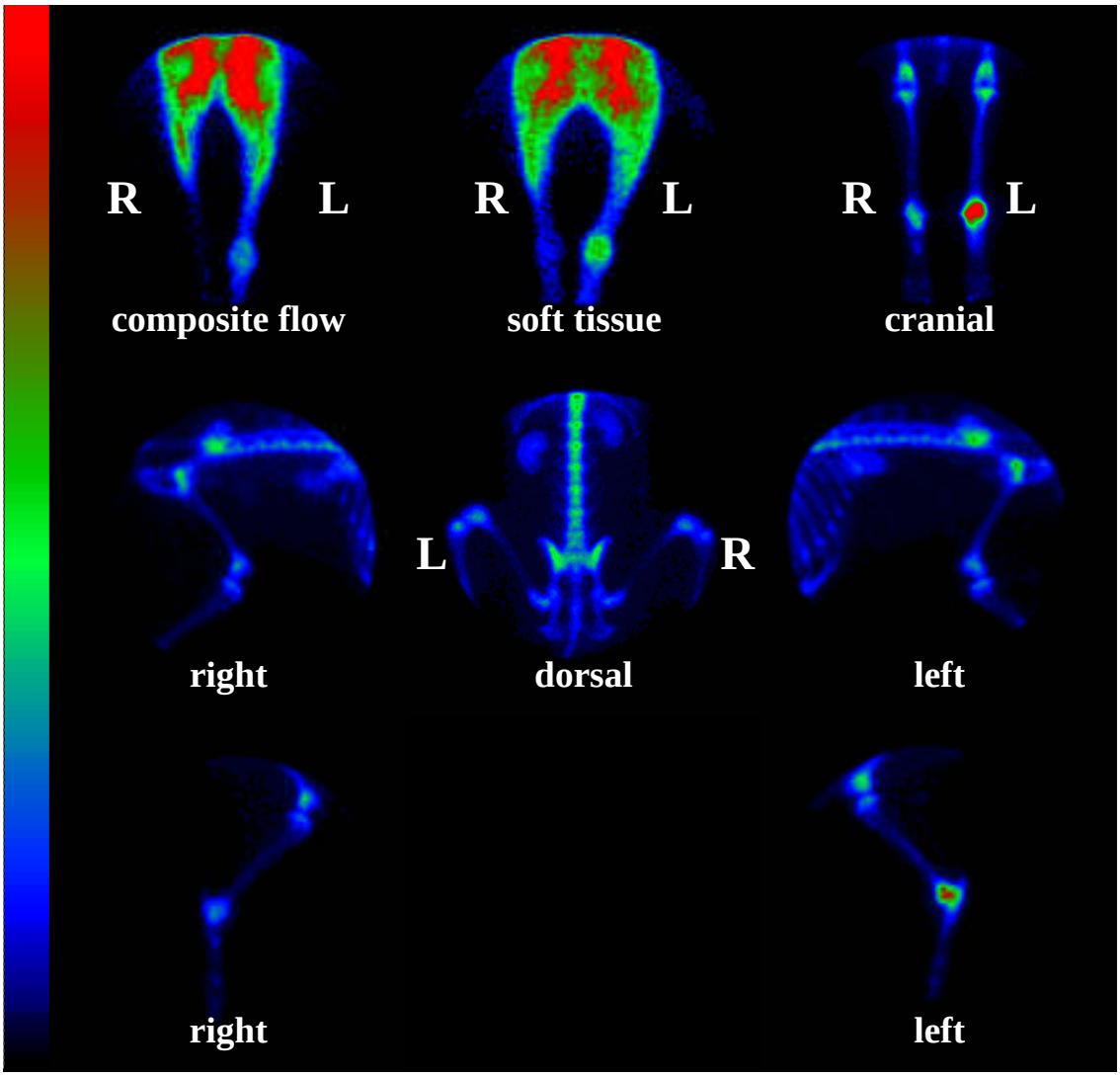

Planar Bone Scintigraphy

Species:	Canine	Breed:	Labrador Retriever
Age:	4 years	Sex:	female
Isotope:	^{99m}Tc	Chemical Form:	MDP

Interpretation: This pattern is most consistent with a marked inflammation of the left tibiotarsal joint. Differentials for this pattern include osteoarthritis secondary to degenerative, traumatic or developmental disease.

3047 Edinger Ave • Tustin • CA • 92780 • Tel: 949-559-7289 • Fax: 949-559-6727
2340 Sepulveda Blvd. • Los Angeles • CA • 90064 • Tel: 310-477-4453 • Fax: 949-559-6727